

NÚMERO 4

VOLUME 1

# SOBRACIBU

SOBRACIBU JOURNAL

## REVISTA

ISSN 2175-3725



# ARTIGO DA CAPA

ANTIBIOTIC PROPHYLAXIS IN SURGERY OF RETAINED  
THIRD MOLARS WITH FIRST GENERATION  
CEPHALOSPORINS: A CLINICAL AND STATISTICAL STUDY  
IN 113 PATIENTS. Barreto AS et al.



SOBRACIBU  
SOCIETY OF ORAL  
BIOLOGY AND  
DENTISTRY  
RESERVADOS



## SOBRACIBU



(C) DIREITOS RESERVADOS

**CONSELHO EDITORIAL /  
EDITORIAL BOARD****EDITOR-CHEFE****DR PAULO AFONSO****COEDITOR****DR EDUARDO CALDEIRA****PRESIDENTE DA SOBRACIBU****DR NELSON CORAZZA  
JUNIOR****VICE PRESIDENTE DA  
SOBRACIBU****DR DANIEL ZERBINATTI****COORDENADOR DA LIGA  
NACIONAL SOBRACIBU****DR FLÁVIO SILVA****EDITORIAL**

IT IS WITH IMMENSE PLEASURE AND A RENEWED SENSE OF COMMITMENT THAT WE ANNOUNCE THE RESTART OF THE JOURNAL OF THE BRAZILIAN SOCIETY OF ORAL AND MAXILLOFACIAL SURGERY AND TRAUMATOLOGY.

AFTER A PERIOD OF HIATUS, WE PROUDLY RESUME OUR EDITORIAL JOURNEY, REAFFIRMING OUR DEDICATION TO ADVANCING THE FRONTIERS OF SCIENTIFIC KNOWLEDGE IN ORAL AND MAXILLOFACIAL SURGERY. FURTHERMORE, IN LINE WITH OUR COMMITMENT TO CONTINUOUS LEARNING AND PROFESSIONAL ENRICHMENT, WE ARE PLEASED TO EXTEND AN INVITATION TO ALL OUR ESTEEMED COLLEAGUES. JOIN US FOR THE 1ST. SOBRACIBU INTERNATIONAL CONGRESS OF ORAL AND MAXILLOFACIAL SURGERY AND TRAUMATOLOGY, SCHEDULED TO BE HELD FROM APRIL 11 TO 13, 2024, IN JUNDIAÍ SP.

THIS IMPORTANT EVENT PROMISES A PLATFORM FOR ACADEMIC EXCHANGE, INTERACTIVE SESSIONS AND NETWORKING OPPORTUNITIES WITH LEADING EXPERTS IN OUR FIELD. IN CLOSING, WE EXPRESS OUR SINCERE GRATITUDE TO OUR CONTRIBUTORS, REVIEWERS, AND READERS, WHOSE UNWAVERING SUPPORT WAS INSTRUMENTAL IN THE RESURRECTION OF JBOMST.

WE INVITE YOU ALL TO EMBARK ON THIS EXCITING JOURNEY OF DISCOVERY AND ACADEMIC PURSUIT AS WE NAVIGATE TOWARD NEW HORIZONS IN ORAL AND MAXILLOFACIAL SURGERY.

YOURS SINCERELY,

PROF. DR. FLÁVIO MARTINS DA SILVA  
RO STATE COORDINATOR  
COORDINATOR OF NATIONAL LEAGUE OF CTBMF  
SOBRACIBU

NÚMERO 4

VOLUME 1

REVISTA

# SOBRACIBU



(C) DIREITOS RESERVADOS

REVISTA SOBRACIBU

SOBRACIBU JOURNAL

COMO CITAR: AUTOR (S) TÍTULO DO ARTIGO. NOME DA REVISTA. ANO; NÚMERO (VOLUME); PAGINAS.

HOW TO CITE: AUTHOR(S) TITLE OF THE ARTICLE. NAME OF THE MAGAZINE. YEAR; NUMBER (VOLUME); PAGES.

APOIO INSTITUCIONAL:



ISSN 2175-3725



NÚMERO 4

VOLUME 1

REVISTA

# SOBRACIBU



(C) DIREITOS RESERVADOS

## SERVIÇO DE CATALOGAÇÃO

REVISTA SOBRACIBU / SOCIEDADE BRASILEIRA DE CIRURGIA E  
TRAUMATOLOGIA BUCOMAXILOFACIAL N.3, V.1, (NOV 2023) - .  
SÃO PAULO: SOBRACIBU, 2023-

TRIMESTRAL.

IDIOMA PORTUGUÊS; INGLÊS; ESPANHOL

ISSN 2175-3725

1. ODONTOLOGIA - PERIÓDICOS 2. MEDICINA - PERIÓDICOS 3.  
CIRURGIA MAXILOFACIAL - PERIÓDICOS  
I. SOCIEDADE BRASILEIRA DE CIRURGIA DE CIRURGIA E  
TRAUMATOLOGIA BUCOMAXILOFACIAL.

BCMF

N4V124

ISSN 2175-3725



## SOBRACIBU



(C) DIREITOS RESERVADOS

## Sumário

USE OF PLANNING IN ORTHOGNATIC SURGERY	01
THE ROLE OF THE SPEECH THERAPIST IN ORTHOGNATIC SURGERIES	10
EVALUATION OF THE KNOWLEDGE OF DENTAL SURGEONS REGARDING PREMALIGNANT LESIONS	21
COVER ARTICLE	
ANTIBIOTIC PROPHYLAXIS IN SURGERY OF RETAINED THIRD MOLARS WITH FIRST GENERATION CEPHALOSPORINS: A CLINICAL AND STATISTICAL STUDY IN 113 PATIENTS	30





**MEDICINA**  
**UNIFACCAMP**  
Centro Universitário Campo Limpo Paulista



**CLÍNICA DE SAÚDE**

**AULAS PRÁTICAS**

**LABORATÓRIOS BEM EQUIPADOS**

**ALTA RECOMENDAÇÃO NO  
MERCADO DE TRABALHO**



*Saiba mais!*



*O seu sonho começa aqui!*

**PÓS**  
**GRADUAÇÃO**  
**UNIFACCAMP**  
Centro Universitário Campo Limpo Paulista

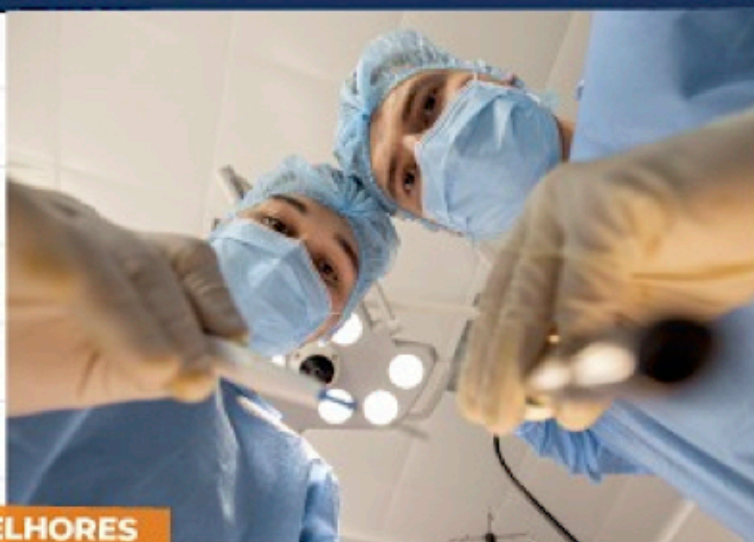
**PÓS**  
**GRADUAÇÃO**



**ESPECIALIZAÇÃO  
EM CIRURGIA  
MAXILOFACIAL**

**3 ANOS DE  
ATIVIDADES PRÁTICAS**

**ATIVIDADES NOS MELHORES  
HOSPITAIS DO BRASIL**



**PROFESSORES DOUTORES COM  
RECONHECIMENTO INTERNACIONAL**

**11 94704-6997**

**11 4812-9400**

**UNIFACCAMP.EDU.BR**



## **Use of 3D planning in Orthognathic Surgery**

Uso de planejamento 3D em Cirurgias Ortognáticas

ELTON GOMIDE<sup>1</sup>  
GABRIELLY ANANDA ROSA<sup>1</sup>  
NAYARA BARBOSA GUIMARÃES<sup>1</sup>  
NICOLY GOMES DA SILVA<sup>1</sup>  
RAQUEL LIMA DE SOUSA TORRICELLI<sup>1</sup>  
MAURO ELIAS GEBRAN<sup>2</sup>  
ALEXANDRA SIQUEIRA MELLO<sup>3</sup>  
DANIEL ZERBINATTI<sup>4</sup>  
FLÁVIO MARTINS DA SILVA<sup>5</sup>  
EDUARDO CALDEIRA<sup>6</sup>

<sup>1</sup>Undergraduates of Dentistry Course - UNIFACCAMP Campo Limpo Paulista, São Paulo State, Brazil

<sup>2</sup>Full Professor of Basic Sciences - UNIFACCAMP Campo Limpo Paulista São Paulo State, Brazil

<sup>3</sup>Full Professor of Basic Sciences - UNIFACCAMP Campo Limpo Paulista, São Paulo State, Brazil

<sup>4</sup>Full Professor of Implant Dentistry - UNIFACCAMP Campo Limpo Paulista, São Paulo State, Brazil

<sup>5</sup>Dental School Coordinator - FIMCA Porto Velho, Rondonia State, Brazil

<sup>6</sup>Full Professor of Maxillofacial Surgery - UNIFACCAMP Campo Limpo Paulista, São Paulo State, Brazil

Contact authors: Flávio Martins da Silva e-mail +55 69 99338-0909

No conflicts of interest

Article received in November 2023

Article accepted in December 2024



## ABSTRACT

At the beginning of orthodontics, the types of exams that had to be used were just photographs of the front and profile of the patients, being at the time the only way to assess the issues and facial proportions. 2D plan radiograph and cephalometric showing the linear and angular dimensions established by bone, dental and facial measurements for years were used to evaluate the correlations of the maxillofacial skeleton, dentition and intra and extraoral soft tissues at all stages of life. Orthodontic reading, including diagnosis, treatment plan, assessment of growth and development, assessment of treatment evolution and stability. However, the delimitations of 2D images are notoriously insufficient, since a third dimension is needed to identify many orthodontic and dentofacial problems. Thus, this study will address the importance of three-

dimensional virtual planning for successful orthognathic surgeries. After evaluating the qualitative bibliographic methodology, it was observed that the reduction of surgical complications when planned in advance with complementary 3D exams, present more stability, realism and consequently more precision in relation to the patient's condition. However, it can be concluded that the 3D virtual planning for orthognathic surgery is extremely important because it provides security to the Dental Surgeon to identify how the entire surgery should be performed and allows to predict better results.

**Palavras-chave:** Ortodontia; Cirurgia ortognática; Tridimensional; Cirurgia

**Keywords:** Orthodontics; Orthognathic surgery; threedimensional; Surgery

## INTRODUCTION

At the beginning of orthodontics, the types of exams that were used were only photographs of the front and profile of patients, which at the time was the only way to assess questions and emotions. But that was not enough, as it made it impossible to make a complete diagnosis and a broad view of the craniofacial set or any other internal complexity of the face, which demanded new methods, forms and specialties in the market to contribute to this advancement and patient care.

Planar radiographs in 2D and cephalometry that present linear and angular dimensions protected by bone, dental and sorcery measurements, have been used for years to evaluate the correlations of the maxillofacial skeleton, dentition and intra and extraoral soft tissues in all phases of orthodontics, including diagnosis, treatment plan, evaluation of growth and development, evaluation of treatment evolution, reading and

stability of these. However, the boundaries of 2D images are notoriously insufficient, as a third dimension is necessary to identify many orthodontic and dentofacial problems. As the 2D images had no depth, they increased the chances of an error or mistake in cases of emergencies or treatments, such as implants, due to their limitation. Patients who can undergo this type of examination are exposed to ionized radiation, and not all patients are indicated to undergo this type of examination<sup>1</sup>.

Image quality depends on the clinician's subjective judgment of the overall radiographic appearance. It is a combination of several characteristics, among which: density, contrast, sharpness and resolution. Digital image quality affects the ability to identify and delineate structures that are important for diagnosis. An image with adequate quality provides enough information for the diagnosis to be



made with an acceptable degree of safety and reliability<sup>2</sup>.

With the emergence of computed tomography technology, scanned plaster models and clinical photos taken in a controlled environment, it became possible to virtually replicate the clinical reality of the patient. As a result, it is possible to plan more adequate bone cuts for each type of dentofacial deformity and to move the bone segments more precisely, which will help in the evaluation and definition of new positions in order to reach a shorter surgery time, in addition to the possibility of simulating the final appearance of the face in real time, allowing a more targeted treatment<sup>3</sup>. The planning is exported to 3D printers that generate surgical guides that replicate the plan on the operating table with a precision of tenths of millimeters. In the 3D method, the vast majority of treatments are stored on digital devices together with patient data. Therefore, any information related to treatments

can be accessed at any time. The necessary data and digitalized dental models are also compressed<sup>3,4</sup>.

Intra-oral scanning (which directly generates computerized digital files of the dental arches) and scanning of old plaster models have aroused the interest of orthodontists in analyzing and diagnosing models. The accuracy of the digital models was validated and considered adequate<sup>3</sup>.

Through the digital models, the possibility of carrying out evaluations of tooth movements by superimposing models in more than one moment was opened, which was not previously possible when the 2D methodology was applied, or in plaster<sup>5</sup>.

## OBJETIVES

With studies and experiences through a bibliographic methodology, this article aims to point out the main positive and essential points of the use of computed tomography

associated with other complementary exams, and the importance of virtual three-dimensional planning for performing orthognathic surgeries.

## RESULTS AND DISCUSSIONS

Through research with exploratory bibliographic methodology, it was observed that the reduction of surgical complications when previously planned with complementary exams in 3D, present more stability, realism and consequently more precision in relation to the patient's condition, thus identifying how the entire surgery should be performed. and allowing to predict better results.

Thus, the three-dimensional virtual planning is an indispensable exam, as the surgeon is able to take the necessary precautions in this delicate surgery, mainly in relation

to essential nerves, depth, thickness and bone structure and areas that must be worked on more or less according to the degree of caution to be taken. With this exam, especially when used in conjunction with panoramic radiographs, it provides the surgeon with more stability and ease during surgery, and allows the patient to better prepare for the pre-surgical and postoperative period. It is also necessary after surgery and recovery to control and monitor the patient in order to identify possible problems or even improvements in relation to the patient<sup>6,7</sup>.

Orthognathic surgery by definition is the dental surgical procedure that aims to seek harmony between the maxillary bones that suffered growth disturbances during the individual's development, resulting in dentofacial deformities compromising the masticatory function and facial aesthetics<sup>8</sup>.



Currently, we can define according to the bibliographical methodology used for the object of study that some software developed specifically for this purpose, allow the professional to project future surgical modifications in the profile and face of the patient on the computer screen. As expected benefits, we can determine: assistance in predicting results, accuracy and reduction of working time both in planning and in surgery. Enabling the passage of safety to the patient through a millimetrically planned procedure, ensuring aesthetic-functional balance. This is possible only through the use of three-dimensional (3D) planning, which allows the junction of the third dimension, making it possible to increase the anatomical structure on the computer screen and interact with the bone structures, without having any changes in the images<sup>5</sup>.

According to Moreira<sup>9</sup>, 3D

planning for Orthognathic Surgery should replace the traditional method as soon as possible in all cases. Where does this interaction of images associated with cone beam computed tomography (CBCT) and image scanning favor the generation of 3D documentation of the patient. The traditional method, plaster models and radiographs suffer distortions after the realization, in addition to the various limitations, and it was in response to these difficulties that three-dimensional planning gained its space within Dentistry. Parallel to this, during a preoperative period, the Dental Surgeon must aim and be responsible for obtaining as much information as possible, so that he can more accurately predict the postoperative period of this patient, and the use of 3D virtual planning allows this target is reached. Several software programs are available for 3D planning, allowing interaction with 3D images and thus simulating

surgery and visualizing the prediction of results in soft and hard tissues. It also discusses how CAD/CAM avoids errors in the traditional modeling process which ultimately lead to suboptimal results<sup>10-16</sup>.

In this way, orthognathic surgery, despite its numerous benefits, needs to be well elaborated and well-studied before being performed, and one of the advantages that the virtual planning method allows is the creation of surgical guides that help in the procedure and satisfactory evaluation of the post results. -operators, thus facilitating the procedure and being an advantage for the duly trained professional and for his patient<sup>9</sup>.

## CONCLUSION

Thus, we can conclude that the use of the 3D virtual method provides greater security to the dentist, allowing the patient's pre- and post-operative period to be predictable by the professional. Obtaining the use of these innovative methods so that the patient feels safe in the procedure and it is

performed in the best possible way.

The construction of this work was intended to contribute to those who are interested in the subject. The literature today lacks the need and importance of using 3D virtual planning in Orthognathic Surgery, with the aim of providing safe patient care.

## REFERENCE

1. Simões, CC; Campos, PSF. Avaliação subjetiva da aceitabilidade das imagens de tomografia computadorizada de feixe cônico para o planejamento de implantes osteointegrados. *Revista de Odontologia da UNESP* [online]. 2014(43):3.
2. Porto, OCLet al. O uso de referências cefalométricas tridimensionais no diagnóstico de simetria dentoalveolar. *Dental Press Journal of Orthodontics* [online]. 2014(19):6.
3. Cintra, O et al. Plataforma digital para planejamento do preparo ortodôntico-cirúrgico de assimetria facial. *Dental Press Journal of Orthodontics* [online]. 2018(23):3.
4. Anacleto, MA; Souki, BQ. Superposição de modelos digitais de maxilares 3D utilizando software de código aberto. *Dental Press Journal of Orthodontics* [online]. 2019(24):2.
5. Brunso, J et al. Guias E Miniplacas Personalizados: Um Protocolo Guiado Para Cirurgia Ortognática. *Rev Esp Cirug Oral y Maxilofac* [online]. 2017(39):1.
6. Silva-Dantas, LA et al. Precisão das Medidas Lineares de Modelos Dentários Digitalizados Através de

- Scanner 3D e Tomografia Computadorizada Cone Beam em Comparação com Modelos de Gesso. CES odontológica. [conectados]. 2019(32):2.
7. Rocha, TL et al. Alterações tridimensionais do espaço aéreo faríngeo após avanço bimaxilar. Dental Press Journal of Orthodontics [online]. 2021(26):05.
8. Hirschhaut M, Flores-Mir C. Diretrizes para Avaliação Ortodôntica e Preparação para Pacientes de Cirurgia Ortognática: Parte 2. Compend Contin Educ Dent. 2022 43(4):215-220.
9. Cavalcanti, MGP; Antunes, JLF; Moreira, L. Planejamento virtual em Cirurgia Ortognática: uma mudança de paradigma. Rev. Bras. Odontol. 2013(70):1.
10. Cavalcanti, MGP, Ruprecht, A; Vannier, MW. Protocolo de ajuste vascular 3D-CT usando computação gráfica para avaliação de lesões maxilofaciais. Pesquisa Odontológica Brasileira [online]. 2001(15):3.
11. Vale, F et al. Planejamento virtual 3D em cirurgia ortognática e geração de talas cirúrgicas CAD/CAM em um paciente com microssomia craniofacial: relato de caso. Dental Press Journal of Orthodontics [online]. 2016(21):1.
12. Aristizábal, JF et al. Abordagem cirúrgica em primeiro lugar com braquetes autoligados passivos 3D personalizados e planejamento cirúrgico 3D: Relato de caso. Dental Press Journal of Orthodontics [online]. 2018(23):03.
13. Modabber A, Baron T, Peters F, Kniha K, Danesh G, Hölzle F, Ayoub N, Möhlhenrich SC. Comparação de simulações de tecidos moles entre dois softwares de planejamento para cirurgia ortognática. Rep. Sci. 2022 12(1):5013.
14. Holte MB, Sæderup H, Pinholt EM. Comparação do registro baseado em superfície e voxel no ramo mandibular para avaliação tridimensional a longo prazo da remodelação condilar após cirurgia ortognática. Dentomaxilofac Radiol 2022;51(4):20210499.
15. Martins, M et al. Planejamento pré-operatório utilizando reconstruções 3D e endoscopia virtual para a localização do seio frontal. Arquivos Internacionais de Otorrinolaringologia [online]. 2011(15):1.
16. Stringhini, DJ et al. Análise por Elementos Finitos de Resistência e Tensão de Diferentes Tipos de Fixação para Cirurgia Ortognática Mandibular. Revista Brasileira de Odontologia [online]. 2016(27):3.

## **THE ROLE OF THE SPEECH THERAPIST IN ORTHOGNATIC SURGERIES**

O PAPEL DO FONAUDIÓLOGO NAS CIRURGIAS ORTOGNÁTICAS

BEATRIZ DA SILVA FIOROTTO<sup>1</sup>

BRUNA CARDOSO SANTANA DE FARIA<sup>1</sup>

HELENITA DA SILVA BARRETO<sup>1</sup>

LILIAN CAMARGO PINTO<sup>1</sup>

NELSON CORAZZA JUNIOR<sup>2</sup>

EDUARDO CALDEIRA<sup>2</sup>

<sup>1</sup>Undergraduates of Speech Therapy Course - UNIFACCAMP Campo Limpo Paulista, São Paulo State, Brazil

<sup>2</sup>Full Professor of Maxillofacial Surgery, Postgraduate Course - UNIFACCAMP Campo Limpo Paulista, São Paulo State, Brazil

Contact authors: Eduardo Caldeira e-mail [eduardo.caldeira@faccamp.br](mailto:eduardo.caldeira@faccamp.br)

No conflicts of interest

Article received in November 2023

Article accepted in December 2023



## ABSTRACT

**INTRODUCTION:** Dental and maxillofacial deformities are associated with changes in the occlusion of the teeth, which, depending on the disproportionate type, lead to changes in the musculoskeletal system. These deformities can lead to alterations and/or adaptations of the oral, speech and maxillary system. **OBJECTIVE:** The aim of this study was to determine the relationship between speech therapy and orthognathic surgery based on bibliographical studies. Literature surveys were carried out without a determined period in the archives of PubMed, SciELO and VHL. **RESULTS:** Fifteen articles were rigorously evaluated taking into account some factors, such as study, purpose, number and sex of participants. The articles were grouped according to their objectives 1) Speech Therapy Group (GF); 2) Modification Group (GM); 3) Technical Group (GT) and 4) Other Group (GO). **CONCLUSIONS:** There are few studies on direct speech therapy, with most studies addressing aesthetic and functional changes in soft and hard tissues in patients undergoing orthognathic surgery. There are also studies aiming at specific methods and/or tests to validate changes in the soft and hard tissues of the facial contour of patients undergoing orthognathic surgery, and a study detailing the pos surgical obtained characteristics.

**Key words:** Speech therapy; Orthognathic surgery; Mandibular Abnormalities; Aesthetics; Function

**Palavras chave:** Fonoaudiologia; Cirurgia Ortognática; Anormalidades Mandibulares; Estética; Função

## INTRODUCTION

Dentofacial Deformity (DFD) is defined as severe skeletal changes associated with changes in dental occlusion. These deformities alter muscle function with disproportionate types, such as functional deviations in mastication, swallowing, breathing and speech; Temporomandibular disorder (TMD), postural changes in the lips, tongue and muscle asymmetry. There are modifications in the orofacial muscle (OMS) due to the muscular response necessary for the function of the Oromandibular (SE) system, this is called<sup>1,2,3</sup> muscular adaptation.

The literature also points out that changes and alterations in the bones and in the bite that can be caused by changes in the orofacial muscular system, guiding facial bone growth, bringing together the sciences of speech therapy and plastic surgery<sup>4</sup>. To correct maxillomandibular bone disproportion, orthognathic surgery is performed to provide balance between stomatognathic functions and harmony between anatomical structures. A plan is carried out for the execution of this procedure together with surgeons and orthodontists, the speech therapist at this stage is essential, as this professional identifies the orofacial

myofunctional alterations present, allowing the realization of a possible rehabilitation<sup>2</sup>.

Promoting stability in surgical results is the role of the speech therapist in the team responsible for patients indicated for the surgical procedure. Speech therapy is important for the area of orthognathic surgery, aiming to favor a better neuromuscular reorganization, rehabilitating the patient after the surgical procedure, contributing to the correction and remodeling of the soft tissues, aiming at the balance between the anatomical functions and the stomatognathic system<sup>2</sup>.

The speech therapy contribution is necessary within the interdisciplinary team to achieve an adequate prognosis, contributing to the execution of the functions of the Stomatognathic System in a harmonious way. In the interdisciplinary team of Orthognathic Surgery, the Speech-Language Pathologist performs the functions of evaluating the Stomatognathic System in the preoperative and postoperative period, offering the patient and the team a comparison between the evaluations, characteristics, compensations and adaptations presented. Speech-language

therapy aims to provide care according to the patient's needs in the pre and post-operative period. The speech therapist assumes an important intervention role in the preoperative period, it is opportune that this work extends until the postoperative phase. According to the suggestion described in the literature, speech therapy intervention has periods and objectives.

In the preoperative phase, it is recommended that the interventions be carried out three months before the surgical intervention, with the aim of clarifying and guiding the patient about the perception of the mechanisms and how the correct muscle patterns work, during the performance of functions and oral rest. This moment of action is important, as information will contribute in the postoperative period in relation to sensory impulses when being sent to the central nervous system, constituting a new proprioceptive system.

The Speech-Language Pathologist can immediately start his post-surgical follow-up respecting the surgeon's release, the literature recommends that this follow-up be after surgery or approximately between 20 and 60 days after the procedure<sup>2</sup>. This intervention can occur in two ways, in the postoperative period where the professional will perform a period of intermaxillary block

and restriction, or in the therapy itself. This professional should always carry out preventive work and reinforce guidance to the patient. Identify the structures of the Stomatognathic System that may cause instability interfering with postoperative rehabilitation. After this more critical phase, a therapeutic intervention can be started where the characteristics presented by the patient will be evaluated, such as a supposed alteration or adaptation in the soft tissues, postural, muscular and functional disorders. From this assessment, muscle exercises and the gradual introduction of foods and awareness and others that are necessary for the patient<sup>5,6</sup> will begin.

The speech therapist working in orthognathic surgery requires committed and dedicated patients who contribute to the execution of the objectives proposed by the therapist. Speech-language pathology discharge can be determined according to the performance and adequate automation of the functions of the Stomatognathic System. After speech therapy discharge, only spaced sessions will be necessary for the evaluator to ensure that there is no possibility of a relapse, however these aspects need more studies<sup>6</sup>.

## OBJECTIVE

Thus, the aim was to identify, based on the scientific literature, the relationship between speech therapy and orthognathic surgery.

METHODS

For the establishment of the research method, the precepts of the Cochrane Handbook were followed. Studies were located and selected through a survey of published texts, without a specific period, in the PubMed, SciELO and VHL databases. In the PubMed database, the articles were selected, limited to research carried out in human beings, in English and Portuguese, using the SciELO and VHL databases, the keywords were used: "Orthognathic surgery and clinical protocols", "Orthognathic surgery and therapy", "Orthognathic surgery and therapy", limited to research carried out in human beings, in Portuguese or English.

The researchers independently searched the texts in the databases in order to mitigate citations. Likewise, citations present in the databases were retrieved and analyzed independently. He was assessed the pertinence of titles and abstracts<sup>7</sup>.

Citations, so that they were selected according to the present study. Citations in languages other than English and Portuguese were excluded, as well as those repeated by

overlapping the keywords. Literatures where there was no direct link to the proposed theme were not considered. In a second moment, the complete texts of the quotations selected by the researchers that were effectively related to the research proposal were analyzed. Those whose complete/integral contents could not be retrieved through the CAPES Journals and/or the journal's official website were also excluded. All stages of the study were conducted independently by the researchers and, when there was disagreement between them, the final position was consensual. Table 1 shows the path of selection of articles for this study.

**Table 1:** Selection and non-selection manuscripts.



Papers	Numbers
Literature review articles	08
Articles with non-main themes	170
Articles without abstract	08
Articles not available for free	22
Selected articles	15

The fifteen (15) selected papers were critically evaluated regarding the type of study, objectives, number and gender of participants, age group, criteria and methods, results and conclusions. Regarding the criteria and methods, we sought to verify and describe the methodology used in each of the articles studied, in order to analyze whether there was homogeneity between them. In the results and conclusions, the general description of the section was carried out, as exposed by the articles.

RESULTS AND DISCUSSION

Based on the objectives, in order to proceed with the analysis and discussion of this section, the grouping of studies into four groups will be adopted, namely: 1) Speech Therapy Group (GF) = studies that addressed intervention and/or direct speech therapy aspects<sup>2,8</sup>; 2) Changes Group

(GM) = studies that reported aesthetic and functional changes in hard and soft tissue<sup>1,6,9-16</sup>; 3) Technical Group (TG) = studies that describe specific exams and/or methods to verify changes in hard and soft tissues<sup>17,18</sup> and 4) Other Group (GO) = studies that did not fit the objectives of the previous groups<sup>19</sup>. As for the type of studies, most are longitudinal descriptive studies (46.5%)<sup>5,8-11,13,16</sup>, followed by cross-sectional studies (26.5%)<sup>1,16,18,19</sup> and case reports (20%)<sup>2,13,15</sup>. The theoretical descriptive type was approached by only one study (7%)<sup>8</sup>.

Regarding the age of the study participants, in general, adult individuals with completed craniofacial growth were listed. The literature recommends that the indication for orthognathic surgery should be performed after the completion of craniofacial growth with the association of orthodontic and surgical resources, in order to correct deformities of the bones of the maxillary and/or mandibular region, since only with orthodontic treatment

would unlikely to make such a correction<sup>20</sup>.

It was possible to verify that there was a prevalence of women who underwent orthognathic surgery in the selected studies. This finding may be related to previous studies that state that there is a prevalence of women seeking orthognathic surgery<sup>21</sup>, in general because women are more concerned with health and aesthetics, in addition to seeking treatment more frequently<sup>22</sup>.

The analysis of the articles regarding the methodology employed, according to the division of the groups, points out that in the FG one study<sup>2</sup> is a case report, and the other article<sup>8</sup> is a theoretical descriptive study that applies the elaboration of a speech therapy therapeutic program for patients submitted to the CO and the process of their content validation. For GM, most of the articles used the methodology of a longitudinal descriptive study<sup>6,9-12,14</sup>, and of these the majority carried out their research in university hospitals in the country and/or abroad, or hospitals of national reference.

Still in this group, two articles<sup>13,15</sup> used the case report. In the TG, the study that used the longitudinal descriptive approach was carried out in the United Kingdom and the other, with a cross-sectional design, did not

specify the location of its performance. In GO, a longitudinal descriptive study that took place in a School of Medicine at São Paulo, was identified. In general, most studies were carried out in teaching hospitals.

The literature shows that these spaces should carry out the integration between research, teaching and assistance, and this premise is present in the official definition of a university hospital, published on the MEC website, one of the regulatory bodies and maintainers of university hospitals in Brazil<sup>23</sup>. This finding may be related to the principles of university hospitals in Brazil, as defended in the literature<sup>23</sup>, which explains that the main hospitals in the world are recognized not only as teaching and assistance centers, but, above all, as knowledge producing centers.

According to the results and conclusions of the studies, in the FG, the researchers found an improvement in the quality of life, in the functions of the stomatognathic system, in the mobility and tone of the muscles, which can be confirmed by means of a standardized clinical protocol<sup>2</sup>.

In one of the studies<sup>8</sup>, researchers were able to design and validate the content of a speech therapy program that contains assessment, therapy (involving orofacial myofunctional exercises, sensory stimulation and functional training) and reassessment. In GM, the researchers found, in general: 1) improvement after performing the OC in relation to self-esteem, mainly in relation to satisfaction with appearance; 2) improvements in social, professional and family relationships; 3) significant reduction in face height due to mandibular repositioning; 4) decrease in the thickness of the upper lip, both in the short and long term, particularly in patients with surgical augmentation of the face height; 5) increase in lower lip thickness in the short term, but decrease in follow-up; 6) several studies found that there were no significant differences in soft or hard tissue changes comparing female and male sex, education and family income; 7) changes in soft tissue landmarks in the pre and post comparison; and 8) improvements in facial aesthetics. In the TG, researchers<sup>17</sup> did not show a statistically significant difference between the two superimposition methods, Voxel Record and 3-D Evaluation.

However, the surface-based record

howed high variability in mean distances between surfaces correspondents in comparison with the Voxel recording, especially in soft tissues. Within each method, there was a significant difference between the superimposition of the hard and soft tissue models. Researchers<sup>18</sup> report that the proposed method significantly aided diagnosis, prognosis, teaching parameters for facial analysis in orthodontics and OC, and in providing guidance and patient follow-up. The GT can be associated with the GM for this analysis, since to verify the anatomical changes, in hard, soft, aesthetic and functional tissues, the researchers used various techniques and/or exams in their research, such as, for example, tomographic images, surface electromyography (EMG), pressure measurement system examination, plaster models, facial analysis periapical radiography, 2-D photogrammetry and, the most used, cephalometry.

Thus, both groups approach objective exams and/or procedures, which sought to evaluate changes in soft and hard tissue, to evaluate masticatory function, in the pre and postoperative moments for comparison and verification of changes, stability and recurrences. Based on the literature, we can state that the exams and procedures used in these two groups are important so that speech therapists, orthodontists and oral and maxillofacial surgeons can use the necessary parameters to carry out an adequate diagnosis, pre and post surgical



evaluation and treatment. These data need to be precisely documented to ensure the best possible result for each patient<sup>18-24</sup>.

## CONCLUSION

The objective was to identify the relationship between Speech Therapy and Orthognathic Surgery. During the literature search, little was found about direct speech-language pathology intervention, with most studies directed to aesthetic and functional changes in the hard and soft tissue of patients undergoing orthognathic surgery. There were also studies that addressed specific methods and/or exams to verify the changes in the soft and hard tissues of the facial profile of patients submitted to orthognathic surgery and a study that detailed the profile of individuals who underwent treatment for dentofacial deformity and Apnea and Hypopnea Syndrome of the Sleep.

**ACKNOWLEDGMENTS:** MFNS Data analysis and/or interpretation; conception and design of the study; carrying out operations and/or experiments; manuscript writing or critical review of its content. LDMT Data analysis and/or interpretation; final approval of the manuscript; conception and design of the study; carrying out operations and/or experiments; manuscript writing or critical review of its content.

## REFERENCES

1. Palomares NB. Impacto das etapas do tratamento orto-cirúrgico na qualidade de vida de pacientes portadores de deformidades dentofaciais [Dissertação de mestrado]. Rio de Janeiro: Faculdade de Odontologia, Universidade do Estado do Rio de Janeiro; 2014.
2. Lima JAS, Luna HB, Pessoa LSF, Alvez GAS. Ganhos funcionais mensurados pelo MBGR e impacto na qualidade de vida em sujeito submetido à cirurgia ortognática: relato de caso. Rev CEFAC. 2015;17(5):1722-30.
3. Pereira JBA, Bianchini EMG. Caracterização das funções estomatognáticas e disfunções temporomandibulares pré e pós cirurgia ortognática e reabilitação fonoaudiológica da deformidade dentofacial classe II esquelética. Rev CEFAC. 2011;13(6):1086-94.
4. Moss ML. The functional matrix hypothesis revisited. 3. The genomic thesis. Am J Orthod Dentofacial Orthop. 1997;112(3):338- 42.
5. Aléssio CV, Mezozone CL, Körbes D. Intervenção Fonoaudiológica nos casos de pacientes classe III com indicação à Cirurgia Ortognática. Arq Odontol. 2007;43(3):102-10.
6. Almeida RCC. Avaliação tridimensional da alteração estabilidade do tecido mole

decorrentes da cirurgia de avanço mandibular [Dissertação de mestrado]. Rio de Janeiro: Universidade do Estado do Rio de Janeiro; 2009.

7. Antwi Effah Kwabena, Owusu-Banahene Wiafe, Boakye-Danquah John, Asare Bernard, Frimpong A.F. Boateng, An automated method for developing search strategies for systematic review using Natural Language Processing (NLP), *MethodsX*, 2023; (10):101-135.

8. Migliorucci RR, Passos DCBOF, Berretin-Felix G. Programa de terapia miofuncional orofacial para indivíduos submetidos à cirurgia ortognática. *Rev CEFAC*. 2017;19(2):277-88.

9. Alves e Silva AC, Carvalho RA, Santos Tde S, Rocha NS, Gomes AC, de Oliveira e Silva ED. Evaluation of life quality of patients submitted to orthognathic surgery. *Dental Press J Orthod*. 2013;18(5):107-14.

10. Jakobsone G, Stenvik A, Espeland L. Soft tissue response after Class II bimaxillary surgery. *Angle Orthod*. 2013;83(3):533-9.

11. Rustemeyer J, Martin A. Soft tissue response in orthognathic surgery patients treated by bimaxillary osteotomy: cephalometry compared

with 2-D photogrammetry. *Oral Maxillofac Surg*. 2013;17(1):33-41.

12. Chen CM, Lai S, Lee HE, Chen KK, Hsu KJ. Soft-tissue profile changes after orthognathic surgery of mandibular prognathism. *Kaohsiung J Med Sci*. 2012;28(4):216-9.

13. Bergamo AZ, Andrucio MC, Romano FL, Ferreira JT, Matsumoto MA. Orthodontic-surgical treatment of Class III malocclusion with mandibular asymmetry. *Braz Dental J*. 2011;22(2):151-6.

14. Gornic C, Nascimento PP, Melgaço CA, Ruellas ACO, Medeiros PJD, Sant'Anna EF. Análise cefalométrica das vias aéreas superiores de pacientes Classe III submetidos a tratamento ortocirúrgico. *Dental Press J Orthod*. 2011;16(5):82-8.

15. Dalla-Bona DE, Matsumoto E, Tanaka E, Tanne K. Tratamento ortognático de um paciente com assimetria mandibular severa e disfunção dos músculos mastigatórios -Relato de um caso clínico. *Rev Fac Odontol*. 2005;46(1):80-9.

16. Veronez FS, Tavano LDA. Modificações psicossociais observadas pós-cirurgia ortognática em pacientes com e sem fissuras labiopalatinas. *Arq Ciênc Saúde*. 2005;12(3):133-7.

17. Almukhtar A, Ju X, Khambay B, McDonald J, Ayoub A. Comparison of the accuracy of voxel based registration and surface based registration for 3D assessment of surgical change following orthognathic surgery. PLoS One. 2014;9(4):e93402.

18. Maniglia JV, Molina FD, Marques CG. Proposta de análise fotográfica do perfil facial em cirurgia ortognática. Rev Med. 2009;88(3/4):168-74.

19. Marques CG, Maniglia JV, Molina FD. Service profile of Orthognathic Surgery of a medical school. Braz J Otorhinol ryngol. 2010;76(5):600-4.

20. Mamani MH. Preparo ortodôntico em casos de cirurgia ortognática [Monografia]. Piracicaba: Universidade Estadual de Campinas, Faculdade de Odontologia de Piracicaba; 2013.

21. Faber J, Faber APMH. Percepções das deformidades dentofaciais: do bem-estar psíquico à indicação de cirurgia. Dental Press J Orthod. 2010;15(4):13-4.

22. Zaroni FM. Características de 485 cirurgias ortognáticas realizadas em um serviço de cirurgia e traumatologia bucomaxilofacial

[Dissertação de mestrado]. Curitiba: Universidade Federal do Paraná; 2015.

23. Araújo KM, Leta J. Os hospitais universitários federais e suas missões institucionais no passado e no presente. Hist Ciênc Saúde. 2014;21(4):1261-81.

24. Yoshida MM, Câmara PRP, Goldenberg DC, Alonso N. Padronização de avaliação em cirurgia ortognática. Rev Soc Bras Cir Craniomaxilofac. 2007;10(4):125-32.



## **Evaluation of the knowledge of Dental Surgeons regarding premalignant lesions**

**Avaliação do conhecimento dos Cirurgiões Dentistas frente a lesões pré-malignas**

GRAZIELE SANTOS<sup>1</sup>  
HELENA VITORIA DE SOUZA FERNANDES<sup>1</sup>  
MALLY DE SOUSA<sup>1</sup>  
MARIA EDUARDA CAVALCANTE DA SILVA<sup>1</sup>  
MARIA EDUARDA LIMA DA SILVA<sup>1</sup>  
RAFAELLA VICTORINO<sup>1</sup>  
JOSÉ LUIS DA ROCHA SANTOS<sup>2</sup>

<sup>1</sup>Undergraduates of School of Dentistry - UNIFACCAMP Campo Limpo Paulista, São Paulo State, Brazil

<sup>2</sup>Full Professor of Basic Sciences School of Dentistry - UNIFACCAMP Campo Limpo Paulista, São Paulo State, Brazil

Contact authors: José Luis da Rocha Santos e-mail: jose.rocha@faccamp.br

No conflicts of interest

Article received in December 2023

Article approved in December 2023

## ABSTRACT

Oral cancer represents 3% of cancer cases in the world, approximately 650,000 people a year are diagnosed with head and neck cancer. It is estimated that in 2030 there will be around 27 million people. Thus, this study aims to evaluate the knowledge of dentists in the Campo Limpo region, if they are able to treat their patients. After evaluating, 90% of respondents are not prepared to detect oral cancer, it was observed that it is necessary to train dentists to detect pre and malignant diseases of the oral cavity.

**Palavras chave:** Cancer; Odontologia; Cavidade Oral

**Keywords:** Cancer; Dentistry; Oral cavity

## INTRODUCTION

The professional trained in

Dentistry, known as a dental surgeon, is responsible for the prevention and treatment of diseases of the stomatognathic system, which consists of the mouth, jaw, facial bones, as well as other structures associated with these parts of the human body, that is, the dentist in general is responsible for assessing the patient's situation and offering the best possible treatment. Premalignant condition or precancerous neoplasm is an injury or tumor that causes multiplication of abnormal cells with an increased risk of developing some cancer, are tissue changes that can assume the character of a malignant tumor at any time, but, on the other hand, can remain stable for a considerable period of time<sup>1</sup>.

Leukoplakia is a clinical term used to describe a predominantly white plaque of the oral mucosa, not removable by scraping, which cannot be clinically classified as any other entity. Its surface may be smooth or rough, being the most frequent precursor lesion

in the mouth. It mainly affects the buccal mucosa and the labial commissures, followed by the alveolar mucosa, tongue, lip, hard palate, soft palate, floor of the mouth and gums<sup>2</sup>.

The causes of injuries are usually associated with smoking, and we are not necessarily talking only about cigarettes, we can mention tobacco, chewing tobacco, cigars, pipes, hookah and the popular electronic cigarette, that is, the greater the number of cigarettes smoked, the greater the risk of cancer; consumption of alcoholic beverages, exposure to the sun without protection; excess body fat and oral hygiene are also factors that cause lesions. The signs to observe are wounds in the oral cavity or on the lips that do not heal for more than 15 days, red or whitish spots on the tongue, gums, roof of the mouth or cheeks<sup>1-4</sup>.

In more advanced cases, the difficulty chewing, swallowing, speaking and great difficulty moving the tongue. Keep an eye out for these signs and the

change in color of your mouth. The disease has a higher incidence in men between 55 and 60 years of age, white and with a low level of education. Oral cancer can be detected in the early stages of the disease, which allows for more effective treatment and cure. Unfortunately, despite the ease of examination of the oral cavity, many cases of oral cancer are diagnosed in advanced stages. It is necessary to be aware of any change in the mouth and if you notice anything out of the ordinary, seek a dentist or doctor. When a suspicious lesion is identified, a biopsy must be performed<sup>1,5,6,7</sup>.

This procedure can be done on an outpatient basis, with local anesthesia, by a trained professional. Some imaging tests, such as computed tomography, also help in the diagnosis and, mainly, help to assess the extent of the tumor. Very early lesions can be evaluated without the need for imaging tests at first. The initial diagnosis allows treatment with better functional results,

and if cancer is confirmed, the patient must be referred for treatment, which in most cases is surgical. Surgery usually consists of removing the area affected by the tumor, in the simplest lesions.

In more complex cases, in addition to surgical treatment, it is necessary to perform radiotherapy to complement the treatment and obtain a better curative result. The Head and Neck surgeon is the professional who will assess the stage of the disease. This evaluation, associated with complementary exams, will determine the most indicated treatment, the interdisciplinary aspect is important (with the participation of several health professionals) in order to prevent complications and sequelae. Squamous cell carcinoma (SCC) of the head and neck with involvement of anatomical sites of the upper aerodigestive tract represents the third most common cause of death caused by cancer in the world<sup>8-10</sup>.

An estimated 11,180 new cases

of the disease in men and 4,010 in women for each year of the triennium 2020-20221. From this, in the daily routine of dental offices, the care of this patient should be a routine. As this is a specialized and delicate area, the dentist must not only know about dental indications, but also about the process of cancer diagnosis, staging and planning of oncotherapy<sup>1-6</sup>.

All of this content is not provided in undergraduate courses in Dentistry or in most postgraduate courses. With a flaw in the construction process of dentists' education, assistance to cancer patients becomes limited, since dental professionals do not have the necessary knowledge to deal with delicate situations during the treatment of a serious pathology such as cancer.

## OBJECTIVES

This work aims to understand the knowledge of dentists in the region of Campo Limpo Paulista, São Paulo State. About pre-malignant lesions in the oral cavity, understand what behavior they practice, if they are able to treat and diagnose in their office.

## METHODS

Qualitative research, was carried out in order to know if the dentist feels able to treat an orofacial lesion. Eight dentists working in the Campo Limpo Paulista region were selected to participate in the research. The base questionnaire contained training, type of specialty or residency, and whether the professional felt capable of diagnosing and treating a pre-malignant lesion.

## RESULTS AND DISCUSSION

Among all types of cancer, oral

cancer is the seventh most frequent malignant neoplasm in the Brazilian population, representing about 3% of the total<sup>3-5</sup>. Most cases of oral cancer are detected at an advanced stage and have the highest mortality rate among head and neck cancers. This reality may be associated with the absence of symptoms, particularly pain, at this stage, or the failure of dentists to carry out a detailed clinical examination of the oral cavity in routine appointments<sup>1-6</sup>. In our study, we interviewed 8 (eight) dentists from the Campo Limpo Paulista region, where we asked some questions to assess their conduct. Therefore, the dental surgeon is able to treat an orofacial lesion.

Of the eight surgeons, five of the interviewees reported not knowing how to make a diagnosis of oral cancer, two reported being able to observe a change in the oral cavity, requiring referral to a doctor to conduct the diagnosis, and only 1 surgeon said he knew how to make the diagnosis in stages advanced.



"A lesion on the tongue, lesion on the palate, on the floor of the mouth, you can detect it, but I think it has to be a little advanced" said the surgeon.

Of the interviewees, we have the following specialties: Oral and Maxillofacial Surgery, Implant Dentistry, Stomatology, Pathology, Health Management, Periodontics, Family Health and General Practice. And of the 8 interviewees, only one has a specialty and knows other professionals who work in this area, the other surgeons do not know any "colleague" from work, with a specialty in stomatology, and end up advising the patient to seek a doctor, devaluing the profession.

Most dentists have little scientific knowledge to care for patients with cancer. One of the factors that, according to the authors, is associated is the deficiency in the training of undergraduate and graduate students<sup>3</sup>. There is a lack of knowledge and training on the part of both the medical team and dentists without specific guidance on

how to perform an adjuvant protocol to antineoplastic treatment to prevent oral complications.

However, the Ministry of Education and Culture does not make it mandatory to include the discipline Oncology in its curriculum, entering as an optional topic in special patients or even in Stomatology. In addition, there are few oncology treatment centers with experienced dentists integrated into their multidisciplinary team<sup>1-8</sup>.

In addition, according to them, there is also a difficulty in finding this type of professional in private clinics to provide a service to the oncology community. In one study, it was also observed that only 35% of patients being treated for cancer in the Head and Neck region had follow-up with the dentist. Due to this devaluation in the market, many end up not studying the subject. According to the British Association of Head and Neck Oncologists, there is a need to implement specialists with training and experience to promote

effective oral care in cancer patients,  
since it is a delicate treatment with  
several complications in the life of the  
patient and family<sup>5-8</sup>.

## CONCLUSION

Thus, after evaluating the results, we can conclude that despite the great importance of the insertion of the dental surgeon in the multidisciplinary oncology team, this is still limited, especially due to the restriction of knowledge of dentistry professionals. The number of cancer cases has been growing in Brazil, and with the increase in the population and increase in life expectancy, this number will grow even more. Due to this, there will be a need to qualify professionals for a specialized reference service, since oncological treatment is very delicate, requiring closer monitoring by professionals.

## REFERENCE

1. INCA, Câncer de Boca.  
02-05-may 2022.  
<<https://www.inca.gov.br/assuntos/cancer-de-boca>>
2. SCIELO, Câncer Oral, 14-03-marc 2022.  
<<https://www.scielo.br/j/cadsc/a/8tftpDdZRzsmjkySfmSVPgt/?lang=pt>>
3. SCIELO, Oral cancer, 22-06-jun 2022.  
<<https://www.scielo.br/j/ramb/a/bzBgX5jfrxz6gDNX7KdC9jM/?lang=en>>
4. SCIELO, Epidemiology of Cancer, 27-02-feb 2022.  
<<https://www.scielo.br/j/rbepid/a/FhV9yH8rF9sXyHttrdzSpj/?lang=en>>
5. SCIELO, Cancer, 17-02-feb 2023.  
<[http://old.scielo.br/scielo.php?pid=S1808-86942013000200018&script=sci\\_arttext&tlng=pt](http://old.scielo.br/scielo.php?pid=S1808-86942013000200018&script=sci_arttext&tlng=pt)>
6. INCA, Números do Câncer, 22-06-jun 2022.  
<<https://www.inca.gov.br/numeros-de-cancer>>
7. INCA, Campanhas, 16-07-jul 2022.  
<<https://www.inca.gov.br/campanhas/cancer-de-boca/2020/semana-nacional-de-prevencao-do-cancer-bucal>>
8. Repositório UFPB, 21-03-feb 2022.  
<[https://repositorio.ufpb.br/jspui/handle/123456789/13187?locale=pt\\_BR](https://repositorio.ufpb.br/jspui/handle/123456789/13187?locale=pt_BR)>
9. INCA, Dados Brasil, 18-02-Feb 2022.  
<<https://www.inca.gov.br/sites/ufu.sti.inca.local/files/media/document/livro-abc-3-edicao.pdf>>
10. BVSALUD, SUS data, 19-06-jun 2022.  
<<https://docs.bvsalud.org/biblioref/colecionasus/2013/30583/30583-552.pdf>>

**ANTIBIOTIC PROPHYLAXIS IN SURGERY OF RETAINED THIRD  
MOLARS WITH FIRST GENERATION CEPHALOSPORINS: A CLINICAL  
AND STATISTICAL STUDY IN 113 PATIENTS**

PROFILAXIA ANTIBIÓTICA EM CIRURGIA DE TERCEIROS MOLARES RETIDOS COM  
CEFALOSPORINAS DE PRIMEIRA GERAÇÃO: ESTUDO CLÍNICO E ESTATÍSTICO EM  
113 PACIENTES

Ananda Schlittler Barreto<sup>1</sup>

Paulo Afonso de Oliveira Júnior<sup>2</sup>

Isis Bolsonaro Santos<sup>3</sup>

Liliane Maria Dantas Lira<sup>4</sup>

Fernando Afonso de Oliveira<sup>5</sup>

Cirurgiã Bucomaxilofacial pelo Departamento de Cirurgia e Traumatologia  
Bucomaxilofacial da Santa Casa de Piracicaba, SP, Brasil, Preceptora da residência  
em CTBMF da SCP<sup>1</sup>



Mestre em Cirurgia e Traumatologia Bucomaxilofacial e coordenador do Departamento de Cirurgia e Traumatologia Bucomaxilofacial e do programa de residência da Santa Casa de Piracicaba, SP, Brasil<sup>2</sup>

Cirurgiã Bucomaxilofacial pelo Departamento de Cirurgia e Traumatologia Bucomaxilofacial da Santa Casa de Piracicaba, SP, Brasil<sup>3</sup>

Residente do programa de Cirurgia Bucomaxilofacial do Departamento de Cirurgia e Traumatologia Bucomaxilofacial da Santa Casa de Piracicaba, SP, Brasil<sup>4</sup>

Mestrando em periodontia da UNESP Araraquara, Cirurgião Dentista Graduado pela UNESP Araraquara, São Paulo, Brasil<sup>5</sup>

Contact authors: Paulo Afonso de Oliveira Júnior +55 19997362535

No conflicts of interest

Article received in December 2023

Article approved in January 2024

## RESUMO

Uma complicação comumente associada a exodontia de terceiros molares inclusos é a ocorrência de infecção do sítio cirúrgico (ISC), a utilização de protocolos profiláticos é uma medida eficaz na redução dos índices destas complicações, porém muito se discute quanto ao fármaco e à posologia a serem utilizados. Neste estudo clínico retrospectivo, foram comparadas duas abordagens terapêuticas quanto a instalação de infecção no sítio cirúrgico. Cento e treze pacientes submetidos a exodontia de terceiros molares, em clínica particular, seguindo os mesmos protocolos cirúrgicos e foram divididos em dois grupos: Protocolo Profilático: Cefalexina 1g, 2 horas antes da cirurgia, e mais 1g 6 horas após a primeira dose; e Protocolo Preemptivo: Cefadroxila 1g, 2 horas antes da cirurgia, e mantido a cada 12 horas durante 5 dias. Dos cento e treze pacientes, apenas dezoito pacientes

(16%) apresentaram infecção do sítio cirúrgico, e destes, aproximadamente 56% foram submetidos ao Protocolo Profilático, enquanto 44% foram submetidos ao Protocolo Preemptivo. Ambos os protocolos apresentados neste estudo demonstraram baixo índice de infecção nos sítios cirúrgicos em exodontias de terceiros molares de baixa, moderada e alta complexidade, oferecendo aos pacientes procedimentos previsíveis e seguros.

**Palavras chaves:** Profilaxia antibiótica, Infecção, Terceiro molar

## ABSTRACT

The infection of the surgical site is a commonly associated complication to third molar extractions, the use of prophylactic protocols is an effective treatment for the reduction of these complications, although there is a discussion on the type of drug and posology to be prescribed. The present retrospective clinical study compared two different therapeutic

approaches regarding the surgical site infection. One hundred and thirteen patients undergoing third molar extraction in private practice, were submitted to the same surgical protocols and were divided in two groups: Prophylactic Protocol: Cefalexin 1g, 2 hours previously to the extraction, and 1g 6 hours after the first dose; and Preemptive Protocol: Cefadroxil 1g, 2 hours previously to the extraction, sustained each 12 hours for 5 days. Only eighteen (16%) of the one hundred and thirteen patients presented infection of the surgical site, and of these, approximately 56% were submitted to the Prophylactic Protocol, while 44% were submitted to the Preemptive Protocol. Both protocols showed a low surgical site infection rate for low, medium and high complexity third molar extractions, offering predicable and safe procedures.

**Keywords:** Antibiotic Prophylaxis, Infection, Molar third

## INTRODUCTION

Lower third molar extraction is one of the most common procedures performed by oral and maxillofacial surgeons around the world(1). Like every type of surgery, this also has risks and potential complications inherent to any type of surgery (2,3). Among them, alveolar osteitis (OA) from 0.5 to 68.4% (4) and surgical site infection (SSI) from 1.2 to 27% (4) are the two most common postoperative complications related to removal. of the third molar, especially the mandibular ones (5).

**Table 1:** International classification of surgical wounds according to the National Research Council-1964. 100x magnification

Type of surgical wound	General characteristics of the wound	Examples	ISC Estimation
<b>Clean wound</b>	Elective clean wounds that do not invade the viscera or digestive or oropharyngeal, respiratory and genitourinary tracts without breaking the aseptic chain.	Thyroidectomy, herniorrhaphy, plastic surgeries without the use of prostheses.	<2%
<b>Contaminated clean wound</b>	Elective surgeries in the digestive, respiratory, genitourinary or oropharyngeal tracts without the presence of inflammation or suppuration.	Dental oral surgery with or without insertion of implants and biomaterials.	<10%
<b>Contaminated wound</b>	Recent traumatic wounds < 4 hours old or with the presence of inflammation or infection, secretion not observed preoperatively.	Dental surgeries with the presence of dead spaces that facilitate bacterial infiltration or the detection of secretion during surgery.	20%
<b>Dirty wound</b>	Traumatic wounds with evident contamination, devitalized tissue, foreign body, feces or purulent secretion present.	Dental surgeries with pericoronitis or established periodontal disease with purulent secretion.	30-40%

Oral surgery, due to its anatomical location as part of the upper digestive system, can be classified as a clean-contaminated or potentially contaminated surgery or even a dirty wound in the case of pericoronitis (6). The oral cavity is colonized by more than four hundred species of bacteria, with the majority of infections being caused by mixed Gram-positive aerobic and anaerobic microbial flora, in addition to Gram-negative anaerobic bacilli (including *Prevotella*, *Porphyromonas*, *Fusobacterium* and *Bacteroides* spp.) many of them capable of producing beta-lactamases. (7)

In medicine and in hospital environments, antibiotic prophylaxis is widely used routinely in all surgical specialties, one of the most used drugs in all hospitals is cefazolin, a first generation cephalosporin (standardization recommended by Hospital Infection Control Committees (CCIH) and by the Ministry of Health) available exclusively in injectable form. Its spectrum of action

includes Gram positive and Gram negative bacteria including Streptococci and Staphylococci (bacteria very common in SSIs). In cases with predominantly anaerobic flora we can also use metronidazole or clindamycin. Its correct use must always take advantage of the "window of opportunity" confirmed by Burke's studies in the 1960s, thus the antibiotic must be administered 30 minutes before the surgical incision, repeating the dose every 4 hours of surgery (protocols extensively published by CCIH in the great most hospital complexes).

Ren YF et al., in 2007(8), in a meta-analysis study, found that patients who received preoperative antibiotics were 1.8 and 2.2 times less likely to develop SSI and alveolar osteitis, respectively concluding that the use of antibiotics in oral surgery.

Lacasa et al., 2007 (9), through a comparative, double-blind and randomized clinical study with 225



patients concluded that the infection rate in the placebo group undergoing ostectomy (25%) was similar to that of dirty surgery (20 %-40%) and thus justifies the use of preemptive therapy when there is a need to extract third molars with ostectomy. Prophylaxis alone decreased the infection rate to 9%, but only the preemptive therapy group had a significant impact on reducing the incidence of subsequent infection, reducing it to 4%. Since prophylaxis was also effective in reducing infection rates, the authors suggest that prophylaxis has a better safety profile with less cost. These authors conclude by stating that the use of systemic antibiotics should not be disregarded in these surgical procedures.

Monaco et al. 2009(10) evaluated 59 healthy patients subdivided into two groups: the test group amoxicillin 2g and no antibiotics (control group) undergoing dental surgery for orthodontic reasons. They observed that in the test group, there was a statistically significant reduction in postoperative pain in the 7 days after

extraction, and patients had a lower consumption of analgesics. However, this does not justify the correlation between analgesia and the use of antibiotics. Wound infection was a sequel reported in 4 patients in the control group and in 1 patient in the test group; this difference was statistically significant ( $P < 0.01$ ).

Susarla SM et al.(11) in 2011, through a systematic review of 114 articles, these being randomized controlled clinical trials with meta-analyses, proved that the use of systemic antibiotics reduced the rate of postoperative infection by 35%. This fact supports the use of antibiotics prophylactically when the variables are compatible, always including surgeries that involve ostectomies and more aggressive interventions. The estimated incidence of side effects common to the use of these drugs is approximately 1% to 3%. In these conditions, the use of prophylactic antibiotics is justified as they have a greater benefit than potential harm.

Oral systemic antibiotic therapy should be

administered preoperatively and continued postoperatively for 2 to 7 days in contaminated or dirty surgeries, the authors conclude.

Lodi G et al. 2012(12) also follows the same line, stating that the use of antibiotics is associated with an increase in generally mild and transient adverse effects compared to placebo.

Moreno-Drada, JA and García-Perdomo, HA 2016(13), carried out a systematic review with meta-analysis of 14 articles, involving 2,063 patients and also concluded that the incidence of infection in the oral cavity decreased with the use of antibiotic prophylaxis.

Lang MS et al. 2017(14), states that systemic antibiotic therapy, regardless of the type, dose, frequency or pattern of use, is associated with a reduced risk of inflammatory complications, specifically OA or SSI, after third molar injury.

For Marcussen KB et al. 2016(15), the development of bacterial resistance to

antibiotics should always be remembered when using antibiotics prophylactically or in therapies. However, there are no studies that relate prophylactic doses as a cause of the development of bacterial resistance.

The topic is still quite controversial in dentistry and there are numerous studies that criticize the use of systemic antibiotics in oral surgery and there is no unanimity yet, unlike what occurs in medicine. For this reason, the oral and maxillofacial surgeon faces a major ethical dilemma when recommending a therapeutic regimen with systemic antibiotics to patients who will undergo surgical procedures for the extraction of impacted teeth. The lack of pharmacological protocols in dentistry for these types of procedures led to the initiative to collect data from patients treated with systemic antibiotic regimens, using these medications in a more rational and objective way.

Therefore, it seems logical to use existing protocols published by hospital

infection control committees, adapting drugs for oral administration. Some studies, including meta-analyses, demonstrate that the incidence of infections decreases with the use of antibiotic prophylaxis in comparison with placebo in patients undergoing tooth extraction.(13) However, there are still risks of indiscriminate prescription of antibiotics that can, if used incorrectly, generate the development of resistant organisms, gastrointestinal disorders, toxicity and the development of allergic reactions(16). Based on this, the use of antibiotic prophylaxis must be well considered and correctly indicated to patients undergoing more invasive surgeries or in patients with pre-existing diseases or immunocompromised individuals that may affect the individual's humoral and cellular defense (6).

The main objective of this study was to evaluate the incidence of post-extraction infection of impacted third molars, using two pharmacological

protocols with 1st generation cephalosporins.

## METHODS

One hundred and thirteen patients (113) who underwent dental surgery to extract impacted third molars in various positions, in a specialized clinic, in the city of Piracicaba-SP between 2003 and 2018, operated by a single surgeon, where they were strict surgical asepsis and antisepsis protocols were used, patients allergic to beta-lactams and patients with pre-operative acute infectious conditions were excluded from the study, patients with metabolic diseases, obesity and general health status higher than ASA I were also excluded from this study. Data such as anamnesis, clinical and radiographic examination, medication used in surgeries as well as trans and post-operative findings were collected from the digital medical record, meticulously described and detailed the evolution and complications of each case.

The 113 patients were subjected to

two types of medication protocols and divided into the following groups: Prophylactic protocol: Cephalexin 1g, orally, 2 hours before surgery and another 1g 6 hours after the first dose, thus following the format of protocols recommended by the CCIH and Preemptive protocol: Cefadroxil 500mg, orally, starting prophylactically with 1g, 2 hours before surgery and maintained every 12 hours for 5 days, this period was established based on studies (4) that describe a period of 5-7 days for the development of alveolar osteitis (OA) and because it is a preventive protocol, that is, the infection had not yet set in but there was a greater chance of it developing, we therefore adopted this period of 5 days of therapy. On the other hand, SSI can occur on average 23.2 days after the procedure.

In both groups, patients took preoperative corticosteroids orally (dexamethasone) or intramuscularly (betamethasone). They were also instructed to rinse their mouth with 0.12% Chlorhexidine digluconate starting 1 day

before surgery and, for the post-operative period, non-steroidal anti-inflammatory drugs and analgesics were recommended, as needed.

The medicines were chosen based on the spectrum of action and generation equal to cefazolin but for oral use, acting against *Streptococcus* sp and *Staphylococcus* sp, common germs in the oral cavity, both being antibiotics from the class of first generation cephalosporins such as cefazolin, these cephalosporins have a spectrum more effective against *Staphylococcus* sp compared to amoxicillin, therefore presenting significant advantages in prophylactic use in surgery. Cephalexin was used preferentially in prophylaxis due to its short interval between doses 6/6h and Cefadroxil in preemptive treatment, due to its greater dosage comfort 12/12h suitable for therapy for more days, both medications have a very antibacterial spectrum similar.

To perform the surgeries,

appropriate instruments, 702 surgical drills and a multiplier piece with external gravitational irrigation of 0.9% saline solution were used, always using sterile drapes, aprons and gloves.

The choice of therapeutic protocols took into account the following factors: degree of surgical difficulty, patient age, likely surgical time and number of elements to be extracted.

We used the methodology proposed by Freudlsperger C et al 2012 (17), to classify the degree of difficulty of third molars based on a scoring system, using a combination of the Pell-Gregory and Winter classifications (18), as proposed by Koerner KR,1994(19). The position of the lower third molar was assessed using a series of parameters of 3 variable categorical positions: inclination of the longitudinal axis of the molar, depth of impaction and available space in relation to the ascending mandibular ramus. These position parameters were evaluated using 4 tracking lines on each

patient's preoperative orthopantomographic radiographs: 1) the occlusal plane line of the mandibular first and second molars; 2) the cervical line of the first and second molars; 3) the anterior margin of the ascending ramus; and 4) the longitudinal axis of the third molar. The longitudinal axis forms an angle with the occlusal plane, providing objective classification of its angulation as follows: horizontal ( $0^{\circ}$  to  $30^{\circ}$ ), mesioangular ( $31^{\circ}$  to  $60^{\circ}$ ), vertical ( $61^{\circ}$  to  $90^{\circ}$ ) and distoangular ( $>90^{\circ}$ ). Subsequently, all molars were separated into difficulty levels 1, 2 and 3, with level 3 being the most complex.

The following patient characteristics were recorded, the variable of interest (response variable) Y: Infection (0 = no, 1 = yes), in addition to the covariates (variables with possible association with the response).

X1: Sex (0 = female, 1 = male);

X2: Age (in years);

X3: Number of teeth extracted during surgery (1; 2; 3; 4; and  $>4$ );



<p>X4: Type of preoperative protocol (1= prophylactic, 2= preemptive);</p> <p>X5: Complication during surgery (0= without complication, 1= with complication);</p> <p>X6: Degree of difficulty of the surgery (0= low, 1= medium, 2= high);</p> <p>X7: Type of drug treatment (1=celestone, 2=dexamethasone).</p> <p>To study the association between the factors and the variable of interest, the logistic regression model was adopted, as the response variable is binary with more than one covariate. The logistic link function was used to generate the logistic model presented under the following structure:</p> $(\pi_i) = \log \left[ \frac{\pi_i}{1 - \pi_i} \right] = \beta_0 + \beta_1$ <p><math>i=1,2,\dots,113</math>. em que <math>\beta_0, \dots, \beta_6</math></p> <p>These are the parameters that will be estimated and <math>X_1, \dots, X_6</math> are the factors under study.</p>	<p>It was found that in relation to one hundred and thirteen patients analyzed, ninety-five (84%) did not present infection in any post-operative period, while eighteen patients (16%) presented infection, the clinical signs determining the diagnosis were the presence of pain, fever, late edema after a critical inflammatory phase and purulent secretion when milking the region in a recent or late stage, in both cases they were considered as infection. The analysis of the results showed an imbalance in the proportion of these patients in relation to the variable of interest (post-operative infection), showing favorable rates for the use of any form of protocol, whether prophylactic or preemptive, compared to the rates of Freudlsperger C et al.(17) which can be considered as a control study in which no antibiotic therapy was used.</p>
---	--

Furthermore, it was observed that the relative frequencies of the covariates studied in Table 1 mostly have similar values, initially indicating in a descriptive

## RESULTS

way that these covariates do not have different results for patients with or without infection. Data such as gender, complications during surgery (where no break in the aseptic chain was found), types of pharmacological, prophylactic or preemptive protocol and the use of betamethasone or dexamethasone corticosteroids did not present statistically

relevant data with the drugs used.

Regarding the degree of difficulty of the surgery, there was greater statistical significance between the groups with low, medium and high degrees of surgical complexity, characterizing this item as quite significant for the topic studied, whether or not there was an infection.

**Table 2:** Frequency distribution of some variables under study. 100x magnification

Variables	Infection	
	NO (n=95)	YES (n=18)
<b>Gender</b>		
Male	44 (46,3158%)	10 (55,5555%)
Female	51 (53,6842%)	8 (44,4444%)
<b>Type of Preoperative Protocol</b>		
Prophylactic	62 (65,2631%)	10 (55,5555%)
Preemptive	33 (34,7368%)	8 (44,4444%)
<b>Complication in surgery</b>		
No	67 (70,5263%)	15 (83,3333%)
Yes	28 (29,4736%)	3 (16,6666%)
<b>Degree of difficulty in surgery</b>		
Low	15 (15,7894%)	2 (11,1111%)
Average	22 (23,1579%)	4 (22,2222%)
High	58 (61,0526%)	12 (66,6666%)
<b>Type of drug treatment</b>		
Betamethasone	49 (51,5789%)	10 (55,5555%)
Dexamethasone	46 (48,4210%)	8 (44,4444%)

Of the eighteen patients who had an infection, approximately 83% of them had no complications during surgery (bleeding, missing fragments, coronectomy) and approximately 67% had a high degree of difficulty in the surgery. Observing the type of preoperative pharmacological protocol in patients who had an infection, the prophylactic protocol was used in approximately 56% and the preemptive protocol was used in 44%.

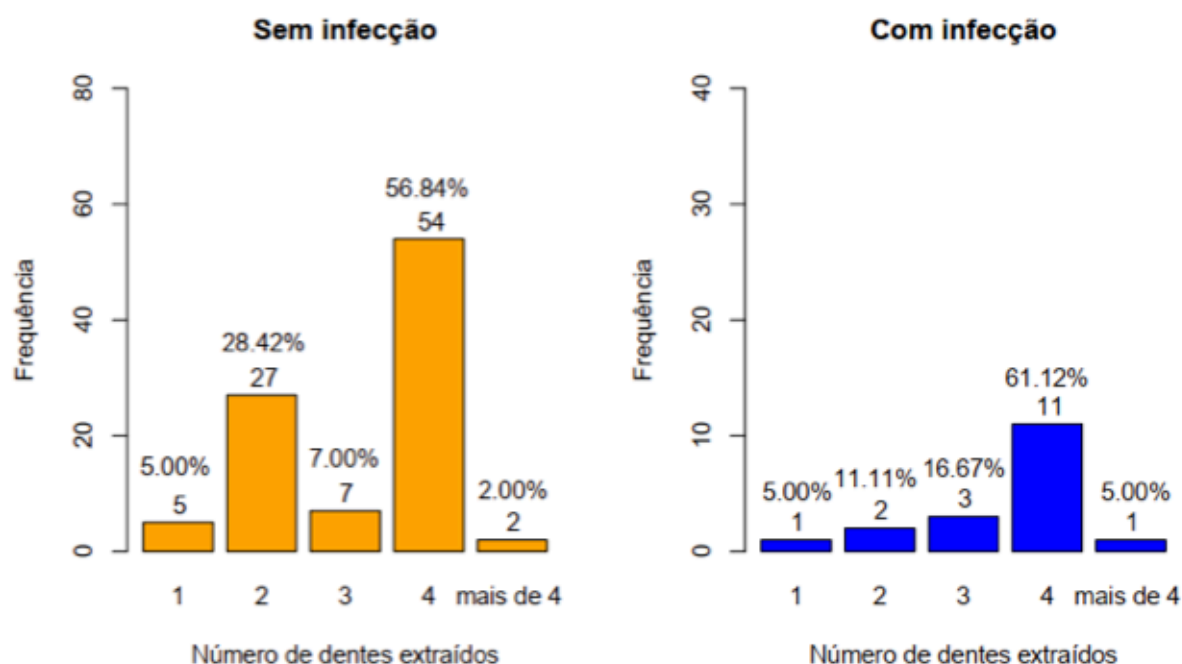
It is important to highlight that the antibiotics used in the treatment of cases of post-operative infection were different from those used in prophylaxis or preemptive treatment, as the occurrence of infection is a clear sign that the causing bacteria would not be sensitive to the drug used, therefore they were used clindamycin 300mg 8/8h or ciprofloxacin 500mg 12/12h or even a combination of the two depending on the severity of the condition.

It is also interesting to note that in

surgeries with low and medium degrees of difficulty, the incidence of infections was 2 and 4%, low rates when compared to the results of Freudlsperger et al. (17) 7.3 and 23.8% in a study considered as control as no systemic antibiotic therapy was performed, and in cases considered difficult by the same authors, the incidence of infections was 29.6%, while our results for these cases were 12%, which represents a significant reduction.

With regard to the covariate age of patients, it was observed that measures of central tendency such as the mean, median, quartiles and variability as coefficient of variation showed different behaviors for patients with and without infection, in addition to observing that the Age distribution represented by Figure 2 showed different behavior and with atypical observations for both types of patients.

**Figure 3:** Number of teeth extracted in relation to the infection variable. 100x magnification



Regarding the covariate number of teeth extracted (fig. 3) in the same surgery, the majority of patients had four teeth removed, regardless of the presence of infection. Although the number of teeth extracted was higher in individuals who did not have an infection, which corresponds to a frequency of 54 observations compared to patients with infection who

have a frequency of 11 observations, in percentage terms the results become more similar, that is, the percentage of individuals without infection and with infection who had four teeth extracted corresponded to 56.84% of the total number analyzed and 61.12% of cases that presented an infectious condition, as shown in Figure 3.

## DISCUSSION

Considering all these studies, the generalized linear model via logistic regression was used to verify whether, in addition to the aforementioned medications, some covariates frequently used in dental surgeries have an influence on the variable response, occurrence or not of infection. Through the methodologies used, it was observed that only the variables age of patients and number of teeth extracted during surgery were significant in relation to variable infection. We opted for the logical connection function, due to the greater ease of interpretation of the parameters and the fact that it is frequently used in scientific articles in the dental field.

Freudlsperger C et al. (17), in 2012, carried out a retrospective analytical study of 443 patients, 228 men (51%) and 215 women (49%), who underwent surgical removal of 585 lower third molars. The patients' ages ranged from 14 to 51 years.

All lower third molars were classified by a scoring system (score 3-10) using a combination of the Pell-Gregory and Winter (18) classifications, as proposed by Koerner KR, 1994(19). In general, no preoperative or postoperative prophylactic antibiotic treatment was administered. Most patients received non-steroidal anti-inflammatory drugs, with dosage adjusted according to established guidelines. For 109 third molars (19%), the extraction difficulty was classified as non-complex (score 3 to 4); for 341 (58%), moderate (score 5 to 7); and for 135 (23%), difficult (score of 8 to 10).

The total rate of postoperative inflammatory complications was 22% (n 129), with the majority of these cases consisting of alveolar osteitis (n 116; 89.9%), followed by surgical site infections (n 10; 7.8%). % and abscess (n 3; 2.3%). Molars classified as not complex for extraction had a postoperative inflammatory complication rate of 7.3%,



moderate molars, 23.8%, and difficult molars, 29.6%. Molars classified as moderate or difficult to extract were more often accompanied by postoperative inflammatory complications than molars classified as non-complex (odds ratio 5.3 and 3.9, respectively,  $P = 0.0001$ ). They concluded that there is a highly significant correlation between the level of difficulty in surgical removal of lower third molars and postoperative inflammatory complications. A preoperative assessment of surgical difficulty is crucial for planning the extraction of the impacted third molar. It is also important to predict possible postoperative inflammatory complications, because more difficult extractions are commonly associated with more serious postoperative complications.

The rate of postoperative inflammatory complications, including alveolar osteitis, surgical site infection and abscess, was relatively high, 22.1%, in high levels of difficulty this number reached 50%. They justify the variation in results compared to other authors due to

the different diagnostic criteria used to identify postoperative inflammatory complications, mainly through clinical observation. Second, most studies focus only on alveolar osteitis, without observing other postoperative inflammatory complications, such as surgical site infection or abscess. Another limitation of most studies is the short follow-up period, which rarely exceeded 1 week. Therefore, late-onset infections, which typically occur approximately 1 month after extraction, are often not included.

Third, study design appears to have an important effect, because retrospective studies generally reveal a lower incidence of postoperative inflammatory complications than prospective studies. They consider that this study presents a valid scoring scale to predict postoperative inflammatory complications, and therefore appropriate perioperative measures can be considered, including the administration of antibiotics. In our study, all cases were reported and had long follow-up periods, unlike many studies in

which cases are underreported, which explains the low statistical rates.

In our results, 18 patients (16%) presented infectious conditions in general. Of these 18 patients, approximately 67% underwent surgeries with a high degree of difficulty, therefore teeth in more complex positions, which is also reported in the literature (20). Observing the type of preoperative protocol in patients who had an infection, the prophylactic protocol was used in approximately 56% and the preemptive protocol was used in 44%.

It is also interesting to note that in surgeries with low and medium degrees of difficulty the incidence of infections was 1.7 and 3.5%, low rates when compared to the results of Freudlsperger C et al. (17) 7.3 and 23.8 % in a study that can be considered control because no antibiotics were used, and in cases considered difficult by the same authors, the incidence of infections was 29.6%, while our results for these cases were 10.6%, which represents significant reduction.

Many studies demonstrate the effectiveness of dexamethasone and betamethasone in controlling pain, edema and trismus after the extraction of impacted third molars (21-23,18,19). Both betamethasone and dexamethasone have lower mineralocorticoid activity, a half-life of 36-72 hours and 25 times greater potency than hydrocortisone in reducing inflammatory mediators that have a lesser effect on leukocyte chemotaxis. In our study, we did not find statistically significant differences between the two drugs in the analyzed factor, presence of infection or not, although clinically the injectable (IM) form of betamethasone with two salts, acetate and disodium phosphate, showed greater postoperative comfort with greater control of patients' edema.

Our analysis suggests that prophylactic and preemptive regimens are effective and safe. In addition to a very detailed anamnesis, the patient's age, degree of surgical difficulty and number of surgical

sites must be well evaluated when indicating individualized therapeutic protocols for each patient. The results suggest carrying out antibiotic prophylaxis to prevent infections in surgeries with flaps and osteotomies and reserving preemptive treatment for surgeries with a higher degree of difficulty, also in patients over 25 years of age. The prophylactic regimen is effective in surgeries involving up to two surgical sites and in young patients, with a low to moderate degree of surgical difficulty. The preemptive regime is indicated for highly difficult surgeries and more than 2 surgical sites according to our statistical findings.

## CONCLUSION

The 1st generation of cephalosporins have proven to be clinically efficient in both prophylactic and preemptive use in oral surgeries for extraction of impacted impacted third molars. It presents an antibacterial

spectrum suitable for oral flora in addition to having extended coverage for staphylococci, an extremely positive fact in the prevention of osteitis and surgical site infections in the oral cavity. The vast majority of studies carried out with systemic antibiotics use amoxicillin, which does not have a comprehensive profile for staphylococci, which is perhaps one reason why many studies consider antibiotic prophylaxis to be ineffective and unnecessary in oral surgery. According to what we observed in the literature, very few studies use first-generation cephalosporins.

The use of differentiated protocols such as preemptive treatment applied to patients who are more likely to develop infectious conditions after surgery, whether due to factors such as immunodeficiencies due to systemic factors and pre-existing diseases or due to the fact that they present risk factors that justify more extended protocols of antibiotic therapy such as age over 25

years, multiple surgical sites, more than two according to our statistics or high degree of surgical difficulty, perhaps it is a more precise indication for extended treatments with 5 or 7 days of antibiotic therapy.

A careful anamnesis combined with the analysis of the risk factors already discussed, such as the patient's age, degree of difficulty and number of elements to be extracted in a single operation, proved to be significantly related to the risk of infection, thus justifying the use of the prophylactic protocol or preemptive specifically for each particular case.

Therefore, the use of prophylactic regimens such as cephalexin 1g 1 or 2 hours before surgery and 1g 6 hours after the first dose appear to be suitable for dentoalveolar surgeries involving osteotomies with the use of flaps for up to two surgical sites in surgeries with a high degree of low or medium complexity and in patients up to 25 years of age.

On the other hand, the preemptive cefadroxil regimen 1g 1 or 2 hours before surgery and 500mg every 12h for 5 days, this treatment period is defined by the fact that there is no infectious condition established and the critical period for infections extends until o 3 post-operative day, considering 5 days to be a good coverage period. It is indicated in cases of moderate to high degree of complexity, in surgeries involving more than 2 surgical sites and in patients aged 25 years or over, patients who have a history of infections in their anamnesis, previous hospital admissions due to infectious conditions and in patients with comorbidities (such as diabetes, obesity), systemic diseases that lead to infections or immunocompromised patients.

Another finding observed in the retrospective analysis of all clinical records used in the research that was not specified in this study is an extremely low rate of side effects associated with the use of 1st generation cephalosporins.

In a simple statistical analysis of the infection rate with the proposed protocols, the data obtained were 1.76% incidence of infections in surgeries with a low degree of complexity, 3.53% of cases of infections in surgeries with a moderate degree of complexity and 10.61% incidence of infection in highly complex surgeries, all rates were lower than those obtained by Freudlsperger C et al.(17), a study with a similar methodology but without the use of antibiotics in the perioperative period.

This study arose from the pressing need to offer our patients safe procedures based on methodologies already used in hospitals and the absence of rational clinical protocols regarding the use of systemic antibiotics in impacted third molar surgeries.

## REFERENCES

1. Abdulkadir Burak Cankaya, Mehmet Ali Erdem, Sirmahan Cakarar, Muhsin Cifter, Cuneyt Korhan Oral. Iatrogenic Mandibular Fracture Associated with Third Molar Removal. *Int J Med Sci* 2011; 8(7):547-553. doi:10.7150/ijms.8.547.
2. Azenha MR, Kato RB, Bueno RBL, Neto PJO, Ribeiro MC. Accidents and complications associated to third molar surgeries performed by dentistry students. *Oral and Maxillofacial Surgery*. 2013 Dec 27;18(4):459–64.
3. Chiapasco M, De Cicco L, Marrone G. Side effects and complications associated with third molar surgery. *Oral Surgery, Oral Medicine, Oral Pathology*. 1993 Oct;76(4):412–20.
4. Reiland MD, Ettinger KS, Lohse CM, Viozzi CF. Does Administration of Oral Versus Intravenous Antibiotics for Third Molar Removal Have an Effect on the Incidence of Alveolar Osteitis or Postoperative Surgical Site Infections? *Journal of Oral and Maxillofacial Surgery*. 2017 Sep;75(9):1801–8.
5. Bui CH, Seldin EB, Dodson TB. Types, frequencies, and risk factors for complications after third molar extraction. *Journal of Oral and Maxillofacial Surgery*. 2003 Dec;61(12):1379–89.

6. Laskin DM. The use of prophylactic antibiotics for the prevention of postoperative infections. *Oral and Maxillofacial Surgery Clinics of North America*. 2003 Feb;15(1):155–60.
7. Flynn TR, Shanti RM, Hayes C. Severe Odontogenic Infections, Part 2: Prospective Outcomes Study. *Journal of Oral and Maxillofacial Surgery*. 2006 Jul;64(7):1104–13.
8. Ren YF, Malmstrom HS. Effectiveness of Antibiotic Prophylaxis in Third Molar Surgery: A Meta-Analysis of Randomized Controlled Clinical Trials. *Journal of Oral and Maxillofacial Surgery*. 2007 Oct;65(10):1909–21.
9. Lacasa JM, Jiménez JA, Ferrás V, Bossom M, Sola-Morales O, García-Rey C, et al. Prophylaxis versus pre-emptive treatment for infective and inflammatory complications of surgical third molar removal: a randomized, double-blind, placebo-controlled, clinical trial with sustained release amoxicillin/clavulanic acid (1000/62.5mg). *International Journal of Oral and Maxillofacial Surgery*. 2007 Apr;36(4):321–7.
10. Monaco G, Tavernese L, Agostini R, Marchetti C. Evaluation of Antibiotic Prophylaxis in Reducing Postoperative Infection After Mandibular Third Molar Extraction in Young Patients. *Journal of Oral and Maxillofacial Surgery*. 2009 Jul;67(7):1467–72.
11. Susarla SM, Sharaf B, Dodson TB. Do Antibiotics Reduce the Frequency of Surgical Site Infections After Impacted Mandibular Third Molar Surgery? *Oral and Maxillofacial Surgery Clinics of North America*. 2011 Nov;23(4):541–6.
12. Lodi G, Figini L, Sardella A, Carrassi A, Del Fabbro M, Furness S. Antibiotics to prevent complications following tooth extractions. *Cochrane Database of Systematic Reviews*. 2012 Nov 14.
13. Moreno-Drada JA, García-Perdomo HA. Effectiveness of Antimicrobial Prophylaxis in Preventing the Spread of Infection as a Result of Oral Procedures: A Systematic Review and Meta-Analysis.




- |  |                        |      |
|--|------------------------|------|
| Journal of Oral and Maxillofacial Surgery. | Maxillofacial Surgery. | 2012 |
| 2016 Jul;74(7):1313–21.                    | Jun;70(6):1280–5.      |      |
14. Lang M, Gonzalez ML, Dodson TB. Do Antibiotics Decrease the Risk of Inflammatory Complications After Third Molar Removal in Community Practices? *Journal of Oral and Maxillofacial Surgery*. 2017 Feb 1;75(2):249–55.
  15. Karoline Brørup Marcussen, Laulund AS, Jørgensen HL, Else Marie Pinholt. A Systematic Review on Effect of Single-Dose Preoperative Antibiotics at Surgical Osteotomy Extraction of Lower Third Molars. 2016 Apr 1;74(4):693–703
  16. Ataoğlu H, Oz GY, Candirli C, Kiziloğlu D. Routine antibiotic prophylaxis is not necessary during operations to remove third molars. *The British Journal of Oral & Maxillofacial Surgery* [Internet]. 2008 Mar 1;46(2):133–5.
  17. Freudlsperger C, Deiss T, Bodem J, Engel M, Hoffmann J. Influence of Lower Third Molar Anatomic Position on Postoperative Inflammatory Complications. *Journal of Oral and*
  18. Pell GJ, Gregory GT. Impacted mandibular third molars: classification and modified technique for removal. *Dent Dig*. 1933;39:e330-e8.
  19. Koerner KR. The removal of impacted third molars. Principles and procedures. *Dent Clin North Am*. 1994;38(2):255-278.
  20. Cervino G, Cicciù M, Biondi A, Bocchieri S, Herford AS, Laino L, et al. Antibiotic Prophylaxis on Third Molar Extraction: Systematic Review of Recent Data. *Antibiotics*. 2019 May 2;8(2):53.
  21. Chaudhary PD, Rastogi S, Gupta P, Niranjnaprasad Indra B, Thomas R, Choudhury R. Pre-emptive effect of dexamethasone injection and consumption on post-operative swelling, pain, and trismus after third molar surgery. A prospective, double blind and randomized study. *Journal of Oral Biology and Craniofacial Research*. 2015 Jan;5(1):21–7.

22. Lima TC, Bagordakis E, Falci SGM, Dos

Santos CRR, Pinheiro MLP. Pre-Emptive Effect of Dexamethasone and Diclofenac Sodium Associated With Codeine on Pain, Swelling, and Trismus After Third Molar Surgery: A Split-Mouth, Randomized, Triple-Blind, Controlled Clinical Trial. *J Oral Maxillofac Surg.* 2018;76(1):60-66.

doi:10.1016/j.joms.2017.06.012.

23. Peterson LJ. Antibiotic prophylaxis against wound infections in oral and maxillofacial surgery. *Journal of Oral and Maxillofacial Surgery.* 1990 Jun;48(6):617–20.



Nossa marca já existe há 55 anos, sendo líder no mercado latino americano e também atuando nos EUA, Alemanha e Paquistão.

Estamos atuando no Brasil desde Janeiro de 2017, importando da nossa fábrica, que possui mais de 55 anos de experiência no mercado mundial, exportando 100% da sua produção para diferentes países.

Agora nossa marca tem como meta ser a maior parceira de profissionais de saúde aqui no Brasil, como já fazemos a anos ao redor do mundo.

Temos certificados internacionais de qualidade como ISO, CE, FDA e no Brasil temos todos os nossos produtos registrados na ANVISA.



#### Para mais informações:

vendas@6bbrasil.com.br  
sac.invent@6bbrasil.com.br

**Empresa:** +55 (11) 3151-6685  
**SAC:** +55 (11) 98710-0073

ACESSE NOSSO QR CODE



@6binventgermanybr  
www.6binvent.com.br



Tudo o que você precisa  
em um único lugar


Toxina  
Preenchedores  
Fio de PDO  
Microcânula  
Bioestimuladores



Viaesthetic®  
*Entregando beleza  
distribuindo qualidade*



(19) 99144-655-8



[viaesthetic.com.br](http://viaesthetic.com.br)



/viaesthetic



@viaestheticoficial

